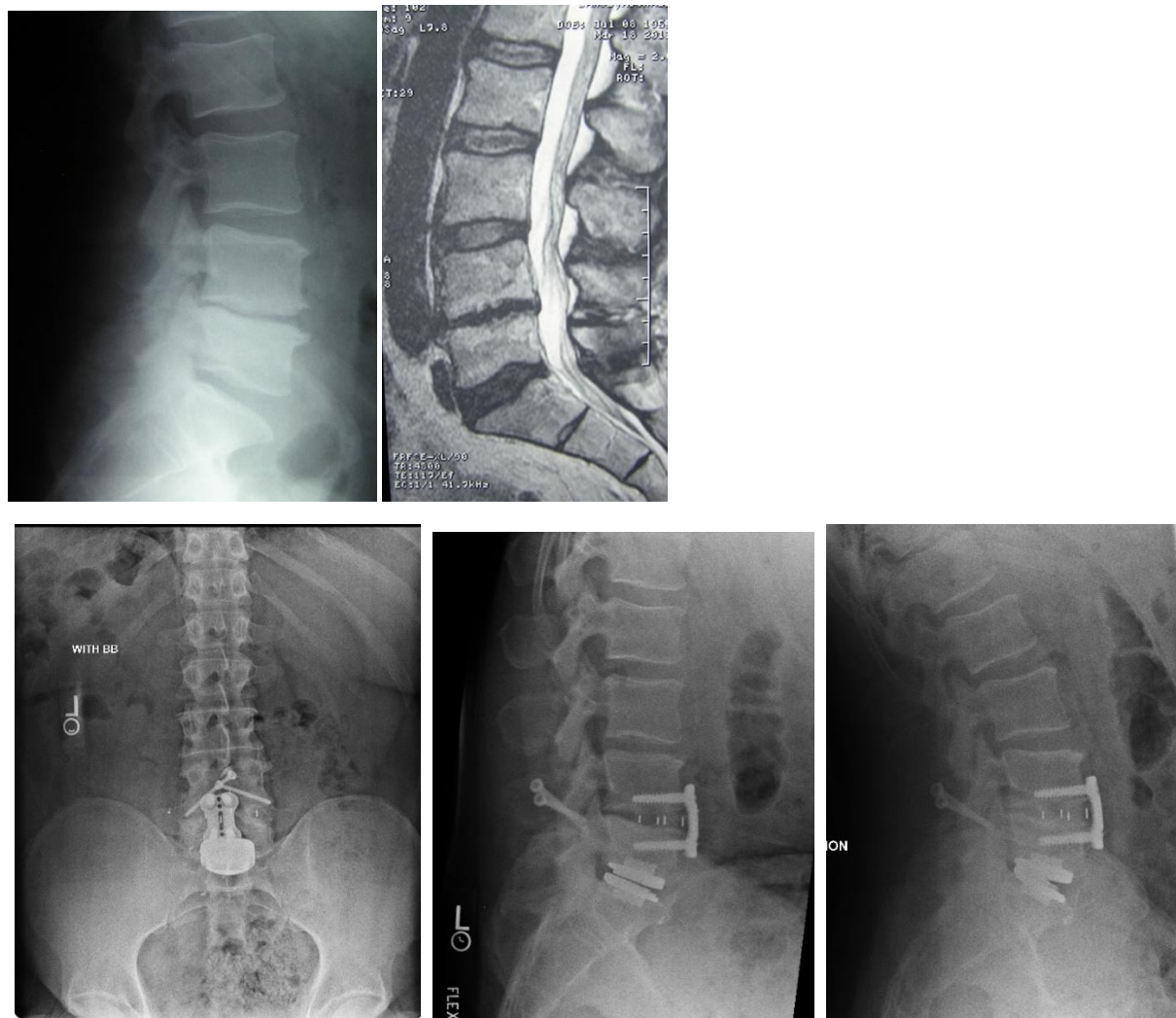


History

57 year old male. 2005: LBP and left leg pain at work from operating forklift. Found to have recurrent HNP at L45. Prior HNP at L45 treated with discectomy in remote past. Symptoms (low back pain, left buttock and leg pain, and left leg weakness) progressed despite nonoperative treatment and then had revision discectomy by Dr. Buttermann. Recurrent symptoms of LBP 6 years later, 2012, after another work injury lifting TVs when unloading truck. Found to have post-laminectomy DDD L45. Failed nonoperative treatment including physical therapy, high dose opioids, and spinal injections.

Treatment

Hybrid surgery April 2013: TDR/decompression L5S1, and ASF/PSF/decompression extension L45.



Outcomes at 3 years

ALL improved, and working full time with 40# lifting restriction.

Pre-operative: 7.5/10 back VAS pain, 7.0/10 leg VAS pain, 74 ODI

Post-operative: 1.0 back VAS pain, 1.0 leg VAS pain, 22 ODI