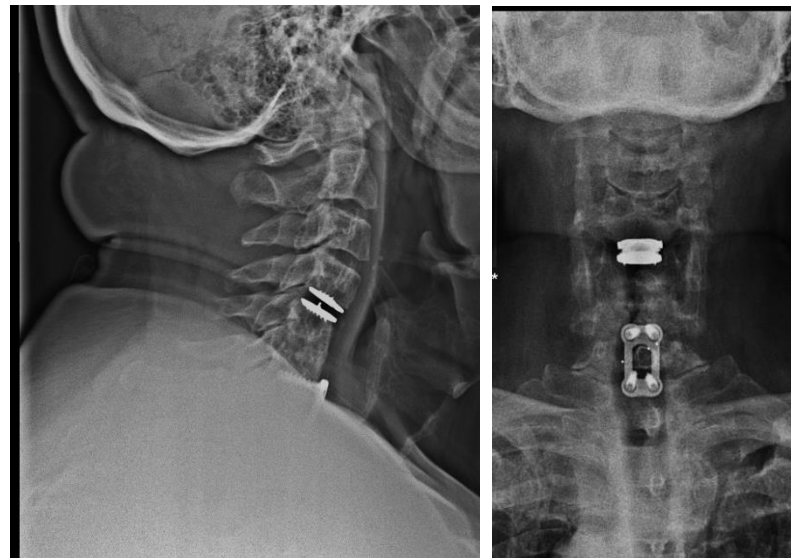
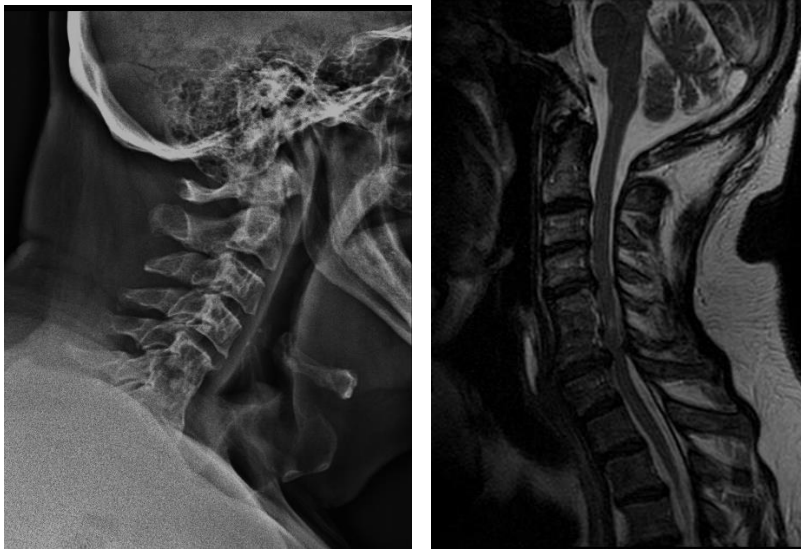

History

62 year old male. 2002: Slip and fall at work with arm caught in sink. ACDF C56 with good result for over 12 years. Symptoms (neck pain, occipital headaches, right arm pain, numbness/tingling, and weakness) progressed 2 years prior to initial Dr. Buttermann evaluation despite physical therapy, injections, and chiropractic. Increased symptoms due to adjacent DDD/stenosis at C45 and C67.

Treatment

Hybrid surgery June 2015: TDR/decompression C45 and ACDF extension C67



Outcomes at 2- years

ALL improved

Pre-operative: 8/10 neck VAS pain, 8/10 arm VAS pain, 64 NDI

Post-operative: 0 neck VAS pain, 1 arm VAS pain, 18 NDI