

# *Outcomes of posterior facet versus pedicle screw fixation of circumferential fusion: a cohort study*

**Glenn R. Buttermann, Tague  
M. Thorson & William J. Mullin**

**European Spine Journal**

ISSN 0940-6719

Volume 23

Number 2

Eur Spine J (2014) 23:347-355

DOI 10.1007/s00586-013-2999-7



**Your article is protected by copyright and all rights are held exclusively by Springer-Verlag Berlin Heidelberg. This e-offprint is for personal use only and shall not be self-archived in electronic repositories. If you wish to self-archive your article, please use the accepted manuscript version for posting on your own website. You may further deposit the accepted manuscript version in any repository, provided it is only made publicly available 12 months after official publication or later and provided acknowledgement is given to the original source of publication and a link is inserted to the published article on Springer's website. The link must be accompanied by the following text: "The final publication is available at [link.springer.com](http://link.springer.com)".**

# Outcomes of posterior facet versus pedicle screw fixation of circumferential fusion: a cohort study

Glenn R. Buttermann · Tague M. Thorson · William J. Mullin

Received: 2 April 2013/Revised: 31 August 2013/Accepted: 31 August 2013/Published online: 2 October 2013  
© Springer-Verlag Berlin Heidelberg 2013

## Abstract

**Purpose** To compare single-level circumferential spinal fusion using pedicle ( $n = 27$ ) versus low-profile minimally invasive facet screw ( $n = 35$ ) posterior instrumentation.

**Method** A prospective two-arm cohort study with 5-year outcomes as follow-up was conducted. Assessment included back and leg pain, pain drawing, Oswestry disability index (ODI), pain medication usage, self-assessment of procedure success, and >1-year postoperative lumbar magnetic resonance imaging.

**Results** Significantly less operative time, estimated blood loss and costs were incurred for the facet group. Clinical improvement was significant for both groups ( $p < 0.01$  for all outcomes scales). Outcomes were significantly better for back pain and ODI for the facet relative to the pedicle group at follow-up periods >1 year ( $p < 0.05$ ). Postoperative magnetic resonance imaging found that 20 % had progressive adjacent disc degeneration, and posterior muscle changes tended to be greater for the pedicle screw group.

**Conclusion** One-level circumferential spinal fusion using facet screws proved superior to pedicle screw instrumentation.

**Keywords** Facet screw · Fusion · Lumbar · Minimally invasive · Outcomes · Pedicle screw

---

G. R. Buttermann (✉)  
Midwest Spine Institute, 1950 Curve Crest Blvd,  
Stillwater, MN 55082, USA  
e-mail: butte011@umn.edu

T. M. Thorson  
University of Utah, Salt Lake City, Utah, USA

W. J. Mullin  
Center for Diagnostic Imaging, Minneapolis, MN, USA

## Introduction

A number of techniques may be used in performing a one-level lumbar fusion for the treatment of advanced degenerative disc disease (DDD) refractory to conservative care. Combined anterior (interbody)–posterior techniques have the advantages of providing the greatest and most reliable increase in disc height, indirect foraminal decompression, restoration of lordosis, and a large area in which to achieve interbody fusion [1, 2]. Interbody fusion may also be performed using a posterior-only approach, such as a posterior (PLIF) or transforaminal lumbar interbody fusion (TLIF). PLIF and TLIF reliably improve clinical results and have the advantage of avoiding the anterior approach but may risk epidural scarring and radiculitis [3–6]. Posterior lumbar surgery has also been shown to adversely affect the posterior paraspinal muscles in experimental and human studies. Electromyographic, histological, histochemical, and inflammatory serum marker changes have been identified and related to the pressure and duration of muscle retraction [7–9]. Experimental animal studies have found magnetic resonance imaging (MRI) changes due to denervation and myonecrosis of the posterior spinal musculature consequent to posterior surgery and retraction duration [10, 11]. Human MRI studies have also detected posterior spinal muscle abnormalities [12–15].

Based on the foregoing, one may conclude that paraspinal muscle retraction should be minimized during posterior lumbar surgery to avoid potential damage to the muscles. One attractive type of minimally invasive posterior fusion technique uses low-profile instrumentation with transarticular facet screw fixation. Clinically, the facet screw technique is generally successful in posterior fusion [16]. However, it has been found that additional interbody fusion enhances the union rate [17]. This combined

circumferential fusion technique has biomechanical stability similar to that of pedicle screws [18–20].

The purpose of the present study was to compare the clinical outcomes and postoperative posterior muscle changes of two groups of patients undergoing one-level circumferential spinal fusion for DDD. In one group, a posterior procedure was performed using a midline approach with pedicle screw fixation, while in the second group facet screw instrumentation was used.

## Methods

The present study is a sub-analysis of a larger ongoing IRB-approved prospective lumbar spine fusion outcomes study. Entry criteria were age between 18 and 65 years, <20° of scoliosis, and axial low back pain (LBP) greater than leg symptoms. Patients were eligible if they had had a previous discectomy but were excluded if they had recurrent disc herniation or stenosis that required additional open decompression. Patients underwent >9 months of nonoperative treatment, including physical therapy, pharmacological treatment, and spinal steroid injections. Two cohorts of single-level lumbar DDD patients were compared, all of whom had circumferential spinal fusion performed by a single surgeon with more than 12 years experience. One group ( $n = 27$ ) was treated between January 2002 and December 2004 with posterior pedicle screw fixation and the other ( $n = 35$ ) was treated between December 2004 and December 2006 with posterior facet screw fixation. All patients gave consent.

There was no significant difference in patient characteristics between the two groups (Table 1). Both groups had a similar “mini” open anterior spinal fusion using femoral

cortical ring allograft combined with bone graft material. All facet screw and nine pedicle screw patients had bone morphogenic protein (BMP, 4.2-mg Infuse, Medtronic, MN) placed within the cortical ring allograft; the remaining patients had anterior iliac bone graft placed within the cortical ring. Patients in the facet screw group had an anterior buttress screw and washer instrumentation placed or, if they were large (>80 kg) or osteopenic/osteoporotic (DEXA scan  $T$  score <−1.5) they had supplementary anterior plate fixation. A total of 16 patients in the facet group had an anterior plate. Both groups had posterior intracortical iliac crest bone autograft harvested for the posterior fusion. BMP was not used posteriorly. Both groups had open posterior instrumentation and decortication out to the transverse processes, yet the degree of midline exposure and retraction was far less for the facet screw group. Additional surgeries were tracked for both groups, including pseudarthrosis repair, adjacent segment decompression, adjacent-level fusion extension, and posterior instrumentation removal. Patients with irritating instrumentation, all in the pedicle screw group, had confirmatory local anesthetic injections ( $n = 10$ ) performed directly over the pedicle screw heads prior to the instrumentation removal.

Clinical outcomes were assessed pre- and postoperatively with multiple outcome instruments: visual analog scale (VAS) for back and leg pain; pain drawing; Oswestry disability index (ODI); pain medication usage (nonsteroidal anti-inflammatory drugs and narcotics); and patient self-assessment of procedure success over a minimum 2-year follow-up period. Outcome results were entered by office personnel (blinded to the type of surgical approach) into computer spreadsheets, with the treating surgeon blinded to these results.

Follow-up lumbar MRI scans were obtained >1 year postoperatively to assess for changes in adjacent disc hydration relative to the preoperative MRI on sagittal T<sub>2</sub>-weighted images. Paraspinal muscle changes were also analyzed: specifically, T<sub>2</sub>-weighted and fat-saturation axial images were analyzed for intensity changes normalized to the psoas muscle at the level of the discs from L2–3 to S1–2; however, L2–3 was not imaged in all scans [15, 21, 22]. In addition, a modification of a previously described digital thresholding technique was used to measure the cross-sectional area of altered muscle in the postoperative relative to preoperative MRIs [22, 23]. T<sub>2</sub>-weighted images were selected at the disc level for each individual (10 total images): L2–3, L3–4, L4–5, L5–S1, and S1–2 for both pre- and postoperative scans. The DICOM images were then imported into an image analysis program that allowed threshold manipulation (Image J, <http://rsbweb.nih.gov/ij/>). The erector spinae muscle area on each side was selected using a loop tool, and the threshold tool was used to highlight the white areas on the T<sub>2</sub> image. The area

**Table 1** Patient characteristics

	Facet screws ( $n = 35$ )	Pedicle screws ( $n = 27$ )
Age (years, mean $\pm$ SD)	38.1 $\pm$ 10.4	42.4 $\pm$ 12.8
Female (%)	86	63
Height (cm, mean $\pm$ SD)	167 $\pm$ 7	169 $\pm$ 10
Weight (kg, mean $\pm$ SD)	71 $\pm$ 14	79 $\pm$ 20
BMI (mean)	25 $\pm$ 4	28 $\pm$ 6
Duration of symptoms (years, mean $\pm$ SD)	4.5 $\pm$ 3.9	4.1 $\pm$ 4.4
Smokers (%)	40	44
WC/litigation (%)	29	33
Fusion levels		
L5–S1	26	19
L4–L5	6	8
L3–L4	3	0

\*  $p < 0.05$

highlighted by the threshold and within the loop was measured in both percentage of selection and pixels. The gray value threshold was determined in a pilot group of ten patients in whom the threshold area was <5 % of the total muscle area on the preoperative scans. The total sample size varied by level owing to image quality and availability (older scans were not digitized). Thus, patients who had both pre- and postoperative MRIs that were usable varied by level: 13 facet and 9 pedicle screw patients at L2–3; 25 facet and 11 pedicle screw patients at L3–4; 27 facet and 12 pedicle screw patients at L4–5; 26 facet and 9 pedicle screw patients at L5–S1; and 21 facet and 10 pedicle screw patients at S1–2.

Fusion status was determined by continuous trabeculation on plain radiographs in all patients, by advanced imaging: high-resolution computed tomography (CT) in 29 patients (average 18 months postoperatively) or MRI (or both) in 56 patients (average 33 months postoperatively). Only three patients of both groups combined did not have advanced imaging.

Statistical comparisons were made between the two groups using a two-sample *t* test for all the outcomes scales. The *p* values from a *t* test comparing the mean change between groups at each follow-up visit were obtained, as was an overall *p* value for a significant difference in mean change over time by group from a repeated-measures regression model. Differences in patient characteristics, pain medication use, self-assessment of success, repeating surgery under similar conditions, recommending treatment to others, and fusion rates were analyzed using the Chi-square and Fisher's exact test. Probability values of <0.05 were considered statistically significant.

## Results

Preoperatively, in the pedicle screw group, the mean number of degenerated lumbar discs on MRI was 1.9

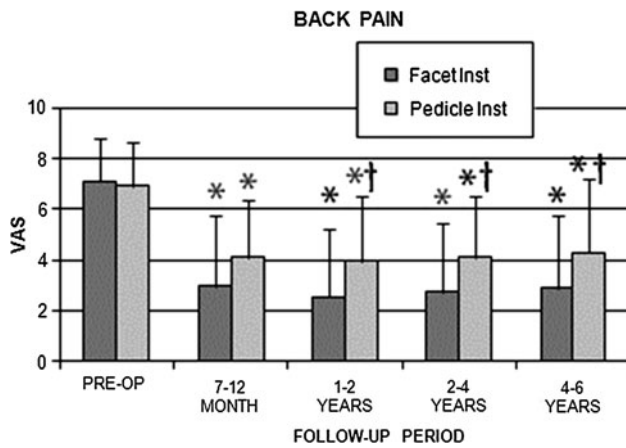
(range 1–5) per patient; 17 patients had preoperative discography (median of 3.0 discs tested, which included a control level), of which a median of 1.0 discs produced concordant pain (greater than or equal to 6/10 pain intensity). In the facet screw group, the mean number of degenerated lumbar discs on MRI was 1.6 (range 1–5) per patient; and 26 patients had preoperative discography (median of 3.0 discs tested) of which a median of 1.0 discs produced concordant pain.

Perioperative comparison between the facet and pedicle screw groups revealed significantly less blood loss, operative time, implant costs (which included BMP), and length of stay for the facet group (Table 2). There were more additional surgeries in the pedicle screw group, primarily owing to irritation and pain caused by the more prominent and bulky instrumentation. For the 13 patients from whom instrumentation was removed, removal was performed  $23 \pm 16$  months after the index fusion procedure. The rate of additional surgeries for pseudarthrosis repair and for extension of the fusion above the index levels was not statistically different between the groups.

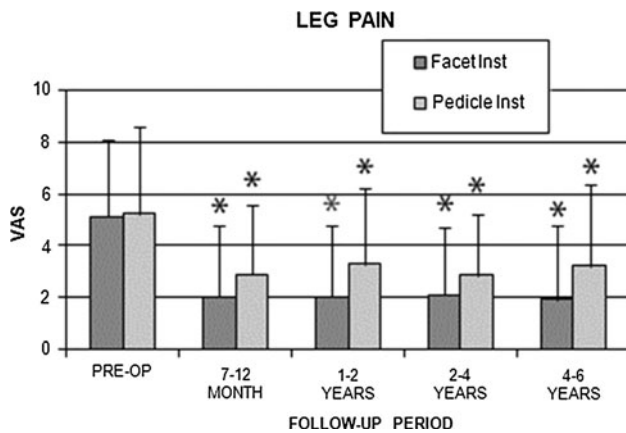
Outcomes data were 100 % for all follow-up periods except at the 4- to 6-year interval, wherein 14 and 7 % of facet and pedicle screw patients, respectively, were lost to follow-up or declined to participate further. The mean follow-up period was 5.6 years. Outcome instruments found significant improvement within both groups at all follow-up periods relative to the preoperative state: LBP VAS, all  $p < 0.0001$  for both facet and pedicle groups at all follow-up periods; leg VAS, all  $p < 0.0001$  for the facet at all follow-up periods and  $p < 0.01$  for the pedicle groups for all follow-up periods except  $p = 0.031$  at the 4- to 6-year follow-up; pain drawing, all  $p < 0.0001$  for both facet and pedicle groups except  $p = 0.009$  for the pedicle group at 1- to 2-year follow-up; ODI, all  $p < 0.0001$  for both groups except  $p = 0.0002$  for the pedicle group at 7- to 12-month and 1- to 2-year follow-up periods (Figs. 1, 2, 3, 4). Pain drawings demonstrated residual pain was

**Table 2** Hospitalization

	Facet screws ( <i>n</i> = 35)	Pedicle screws ( <i>n</i> = 27)	* <i>p</i> < 0.05
EBL (ml, mean $\pm$ SD)	169 $\pm$ 121	381 $\pm$ 249	*
OR time (min, mean)	149 $\pm$ 70	192 $\pm$ 72	*
Length of stay (days)	1.8 $\pm$ 0.8	3.1 $\pm$ 1.0	*
Implant costs (\$, mean $\pm$ SD)	7,219 $\pm$ 2,799	11,932 $\pm$ 14,290	*
Hospital charges (\$, mean $\pm$ SD)	55,342 $\pm$ 18,605	49,157 $\pm$ 8,945	
Additional surgery			
Inst removal	0	13 (48 %)	*
Pseudo repair	0	2 (7 %)	
Adj segment fusion	4 (12 %)	4 (15 %)	
Adjacent-level decompression	2 (6 %)	0	

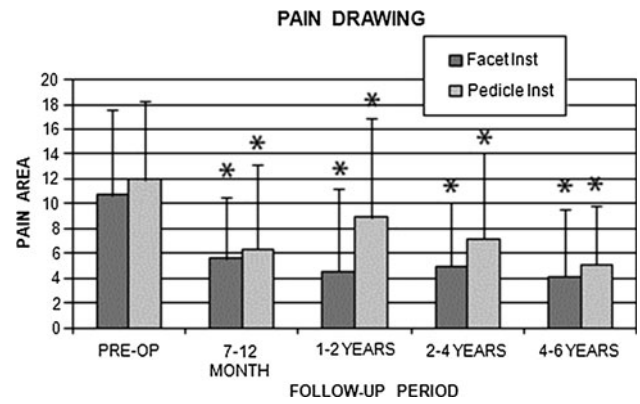


**Fig. 1** Low back pain severity over follow-up periods for facet versus pedicle screw groups (pain VAS, mean ± SD; asterisks indicate significant in-group difference from preoperative value; daggers indicate significant difference between-groups values at indicated time period)

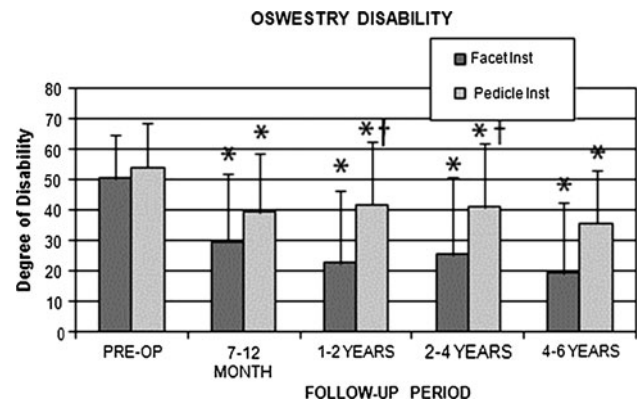


**Fig. 2** Leg pain severity over follow-up periods for facet versus pedicle screw groups (pain VAS, mean ± SD; asterisks indicate significant in-group difference from preoperative value)

typically in the lumbosacral region, buttock, or posterior thigh. Comparison found greater improvement in LBP VAS scores for the facet group, which was significant for the 1- to 2-year, 2- to 4-year, and 4- to 6-year follow-up periods ( $p = 0.028$ ,  $p = 0.033$ , and  $p = 0.039$ , respectively; overall  $p = 0.024$ ). Greater improvement was also found in the facet group for ODI scores, which was significant for the 1- to 2-year and 2- to 4-year follow-up periods ( $p = 0.001$  and  $p = 0.023$ , respectively; overall difference between groups,  $p = 0.020$ ). Outcomes results were reanalyzed to evaluate the effect of the missing patient data for the 4- to 6-year follow-up period on the robustness of the study conclusion. The “worst-case” analysis was performed for the 4- to 6-year end evaluation using two methods. First, for the patients with missing data, we assumed no improvement in any of the VAS pain, pain



**Fig. 3** Low back and leg pain area over follow-up periods for facet versus pedicle screw groups (pain drawing, mean ± SD; asterisks indicate significant in-group difference from preoperative value)



**Fig. 4** Disability severity over follow-up periods for facet versus pedicle screw groups (ODI, mean ± SD; asterisks indicate significant in-group difference from preoperative value; daggers indicate significant difference between-groups values at indicated time period)

drawing, and ODI scores relative to the preoperative state and then analyzed for within-group differences and then differences between the facet and pedicle groups. A  $t$  test was employed to test for statistical significance within group and between groups. The results demonstrate that the within-group changes remain statistically significant after imputing a value of no change for missing data. The between-group differences that were not statistically significant remained nonstatistically significant; however, the difference in LBP VAS at the 4- to 6-year period, which is significant excluding the missing data, is not significant with the imputed data. In addition, the repeated-measures analysis was redone with the imputed data for the missing 4–6 year period. The two parameters with statistically significant differences over time between groups (LBP VAS and ODI) remain statistically significant, with the imputed data sensitivity analysis demonstrating a robust observation and minimal effect on the study conclusions due to the missing observations at the 4- to 6-year period.

**Table 3** Pain medication usage

	Facet screws	Pedicle screws	* <i>p</i> < 0.05
<b>Narcotics</b>			
Preoperative	18/35 (51 %)	16/27 (59 %)	
7–12 month follow-up	12/35 (34 %)	17/27 (63 %)	*
1–2 year follow-up	12/35 (34 %)	9/27 (33 %)	
2–4 year follow-up	13/36 (37 %)	11/27 (41 %)	
4–6 year follow-up	8/30 (27 %)	7/25 (28 %)	
<b>NSAID</b>			
Preoperative	17/35 (49 %)	14/27 (52 %)	
7–12 month follow-up	6/35 (17 %)	6/27 (22 %)	
1–2 year follow-up	12/35 (34 %)	10/27 (37 %)	
2–4 year follow-up	14/35 (40 %)	13/27 (48 %)	
4–6 year follow-up	10/30 (33 %)	12/25 (48 %)	
<b>None</b>			
Preoperative	4/35 (11 %)	1/27 (4 %)	
7–12 month follow-up	13/35 (37 %)	3/27 (11 %)	*
1–2 year follow-up	13/35 (37 %)	3/27 (11 %)	*
2–4 year follow-up	13/35 (37 %)	5/27 (19 %)	
4–6 year follow-up	13/30 (43 %)	7/25 (28 %)	

An additional missing data imputation was conducted in which the 2- to 4-year period observation was imputed for the missing 4- to 6-year period data. The results are similar to those cited earlier, further indicating that the impact on the study conclusions of the missing observations at the 4- to 6-year period is minimal.

Both groups demonstrated substantial reduction in their use of pain medication (Table 3). The facet group used significantly fewer narcotics in the early 7- to 12-month follow-up period and, in the facet group, a significantly greater rate of patients not requiring any pain medication was observed. Assessment of overall success—would patients repeat the surgery under similar conditions, and would they recommend the treatment to others?—was similarly high for both groups (Table 4).

Radiographic analysis identified one and two pseudarthroses in the facet and pedicle screw groups, respectively (an insignificant difference; *p* = 0.41). Postoperative MRIs were obtained in 25 of 27 patients in the pedicle and 31 of 35 patients in the facet screw group at an average of 2.5 years. Of the six patients who did not have a postoperative MRI, four had moved far out of the area and two declined the scan. Postoperative MRI found new or progressive dehydration of the adjacent disc in 20 % of both pedicle and facet screw groups (Fig. 5). This occurred in 25 % of patients who had preoperative discography. The average ( $\pm$ SD) TR and TE were  $4,466 \pm 1,079$  and  $106 \pm 7$ , respectively, on

**Table 4** Self-assessment of success

	Facet screws	Pedicle screws
<b>Overall, do you consider your treatment to have been successful?</b>		
7–12 month follow-up	30/35 (86 %)	21/27 (78 %)
1–2 year follow-up	31/35 (89 %)	20/27 (74 %)
2–4 year follow-up	29/35 (83 %)	21/27 (78 %)
4–6 year follow-up	24/30 (80 %)	19/25 (76 %)
<b>Would you undergo this treatment again under similar conditions?</b>		
7–12 month follow-up	28/35 (80 %)	22/27 (81 %)
1–2 year follow-up	30/35 (86 %)	22/27 (81 %)
2–4 year follow-up	30/35 (86 %)	20/27 (74 %)
4–6 year follow-up	23/30 (77 %)	18/25 (72 %)
<b>Would you recommend to others with symptoms and spine problems to have this?</b>		
7–12 month follow-up	29/35 (83 %)	22/27 (81 %)
1–2 year follow-up	32/35 (91 %)	21/27 (78 %)
2–4 year follow-up	29/35 (83 %)	21/27 (78 %)
4–6 year follow-up	23/30 (77 %)	19/25 (76 %)

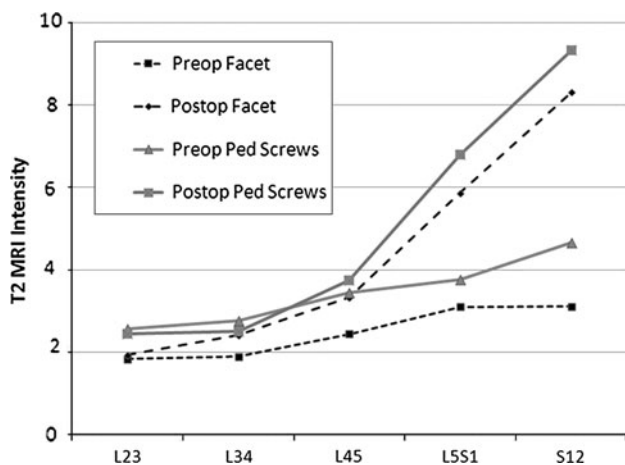
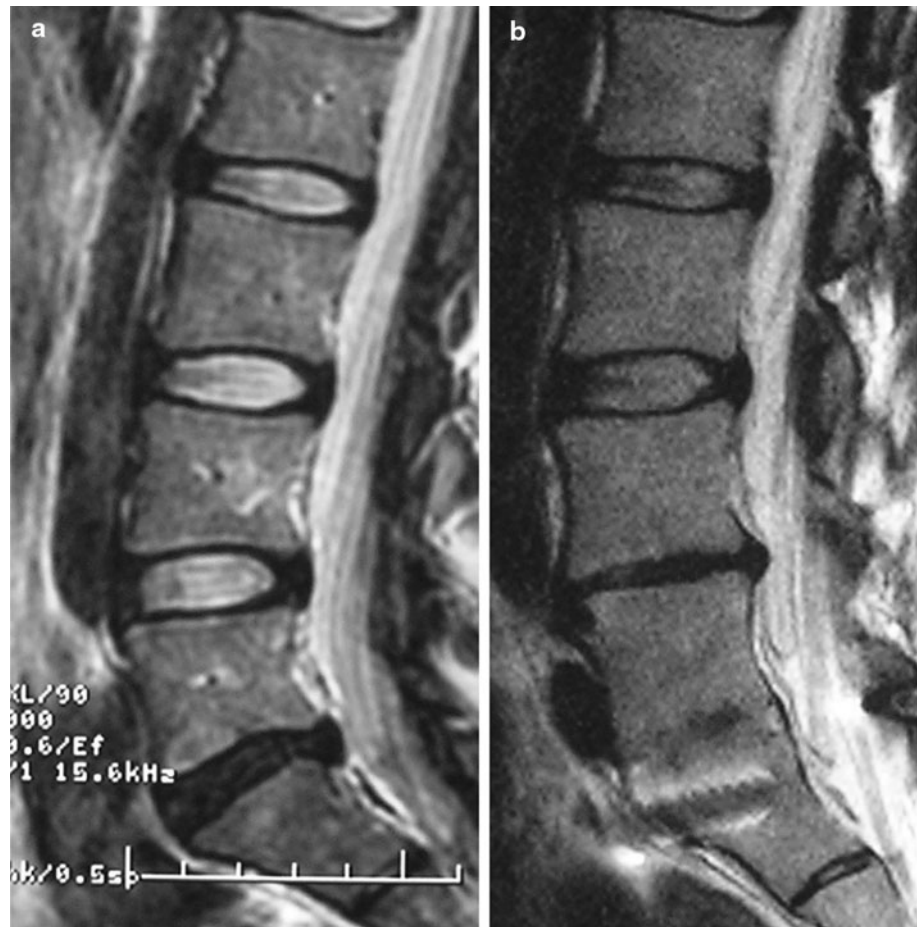\* *p* < 0.05

preoperative MRI and  $4,306 \pm 1,094$  and  $110 \pm 9$ , respectively, on postoperative MRI. The change in T<sub>2</sub>-weighted paraspinal muscle signal intensity, normalized to the psoas, found a small increase from proximal to distal spinal levels in the preoperative MRIs. An increase in T<sub>2</sub> intensity was seen at the surgical levels for both the facet and the pedicle screw groups and was significant relative to the preoperative scans (*p* = 0.001 at L5–S1 and *p* = 0.0001 S1–2) but not between groups (Fig. 6). The area of threshold T<sub>2</sub> signal within the paraspinal muscles (Fig. 7) was significantly greater in the postoperative MRIs at all levels (all *p* < 0.0001 for right, left, and combined right and left) and was greatest at the distal levels (Fig. 8). The increased threshold T<sub>2</sub> signal area within the paraspinal muscles was insignificantly greater for the pedicle relative to the facet screw group at all spinal levels, with no difference between right and left sides.

**Discussion**

The present study compared single-level circumferential spinal fusion operations that varied between two types of posterior instrumentation. Both groups in the present study had significant improvement in pain and disability outcomes and were in the range of prior reports [24, 25]. The present study found decreased blood loss, shorter hospital stay, and a lower reoperation rate for the facet instrumentation group, which is consistent with the previous comparative studies [17, 26, 27]. Fusion rates were high in both groups, and presumably this was enhanced equally by both groups having interbody fusion [17, 26]. However, our study differs from one prior study that found a higher

**Fig. 5** Sagittal MRI T<sub>2</sub> image to assess adjacent-level degeneration and fusion status of index level. **a** Preoperative image of degenerative disc disease at L5–S1. **b** Follow-up demonstrates solid fusion at L5–S1 and development of adjacent L4–5 disc narrowing, degeneration



**Fig. 6** MRI T<sub>2</sub> signal intensity in the posterior paraspinal musculature before and after fusion surgery (mean  $\pm$  SD)

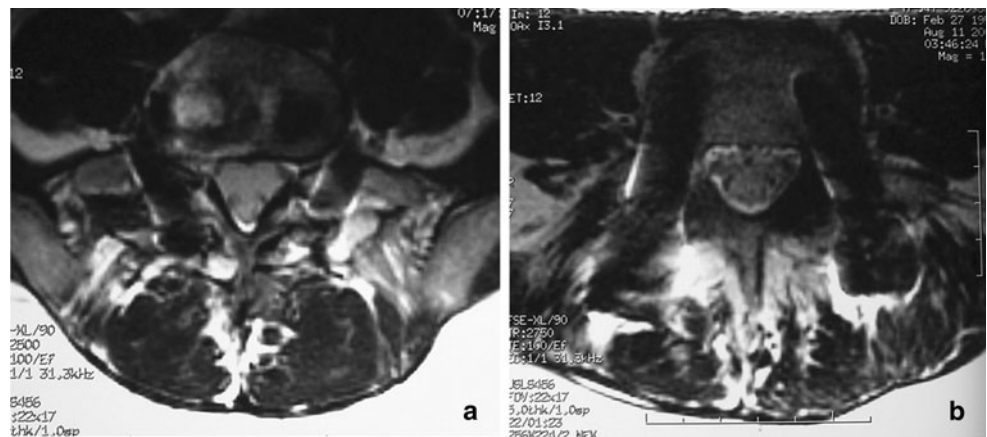
pseudarthrosis rate and no greater improvement of the facet screw over the pedicle screw group [28].

Postoperative MRI found similar rates of adjacent segment disc degeneration for the two study groups. Studies subsequent to enrollment for the present study have suggested that preoperative discography may accelerate this [29].

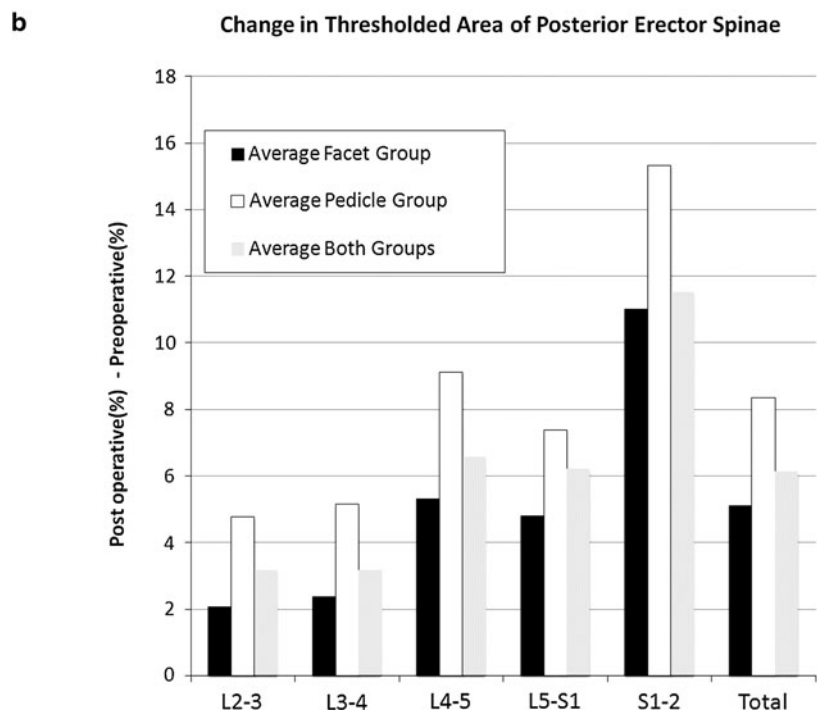
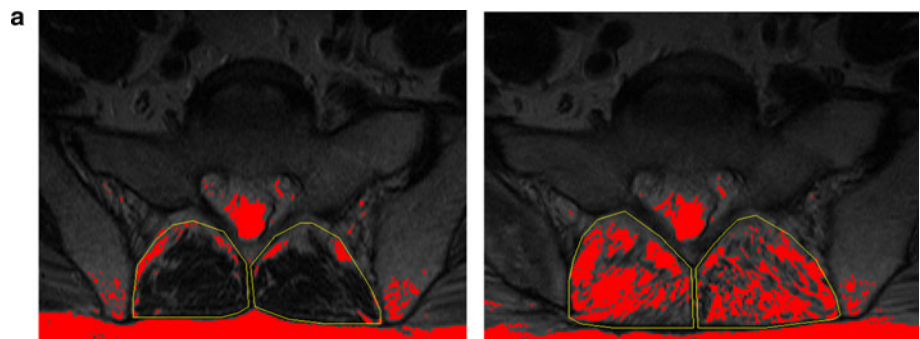
The occurrence of the rate of adjacent segment degeneration was found to be greater in those patients who had preoperative discography. Although this was not significant in the present study, the small sample size may mask the true difference. Postoperative MRI also found increased T<sub>2</sub> signal intensity ratio of the multifidus to psoas (control) muscle, similar to a prior study that also found greater changes in the open fusion group as compared to minimally invasive posterior interbody fusion [30]. The present study found only an insignificant trend for greater MRI muscle change with the more invasive pedicle screw approach. A difference may exist, but our study was underpowered. Alternatively, the fact that the facet group required far less muscle retraction yet the MRI findings were similar between the two groups suggests that factors other than the degree of retraction cause muscle changes. One possible explanation for the similarities of the follow-up MRI between the present study groups is that both had surgical exposure to the transverse processes for posterolateral fusion, with possible concomitant cauterization of the facet vessels and posterior ramus branches. Thus, the MRI changes may reflect denervation changes of the medial and lateral branches of the posterior rami that were at risk of



**Fig. 7** Examples of >1 year postoperative axial lumbar MRI T2 images for facet (left) and pedicle screw (right) patients (b)



**Fig. 8** Change in MRI T<sub>2</sub> signal area (%) in the posterior paraspinal musculature before and after fusion surgery. **a** Example of threshold preoperative and >1-year postoperative T<sub>2</sub> images in a patient at S1–2. **b** Change in threshold areas for facet screw, pedicle screw, and combined groups



injury during the fusion bed preparation. In fact, we have modified our technique and now routinely use an anterior lumbar plate, and posteriorly no longer perform inter-transverse process fusion; rather, we expose only the facet

joint for facet fusion with local bone graft and thus maintain the nerve root posterior rami branches. There is clinical support that more aggressive posterior fusion is not needed [31]. To minimize posterior muscle damage, we

now also use facet screws in multilevel cases (typically with anterior lumbar plates) in place of pedicle screw constructs. However, if osteopenia/osteoporosis and deformity are present (greater than can be corrected by a wedge-shaped femoral ring allograft), then the author uses a combination of facet and pedicle screws.

One limitation of the study is its nonrandomized nature. Another is the incomplete follow-up at the 4- to 6-year period for eight patients. This is a relative weakness as worse-case analysis still found greater improvement for the facet screw group. Another relative limitation is the variable use of BMP (although used only anteriorly). BMP use accounts for probably only a small difference in outcomes, as there was no difference in fusion rates between those in whom BMP was used and those in whom it was not, and postoperative pain drawings did not indicate pain at the anterior iliac bone graft donor sites in those in whom BMP was not used. Another limitation is the variable use of supplemental anterior plate instrumentation in the facet group. This is thought to have negligible effect on outcomes, given that the fusion rate between groups was similar. Limitations regarding the MRI results were notable: Many preoperative scans were not obtained in a digital format, which is required for measurement of muscle alterations; thus the MRI results may be underpowered. In addition, the thresholding technique used to determine the area of altered muscle was dependent on TE and TR settings during MRI acquisition, which varied as noted. Variable MRI field strength and acquisition sequences may also affect signal and contrast between fat and water [32]. This affects our measurements relative to the selected threshold in the area of muscle changes.

The type of “minimally invasive” surgery may vary. Minimally invasive fusion may also be performed using a modification of the open TLIF technique that employs a paraspinal posterior approach. A recent review of this minimally invasive technique concluded that the benefit was only short term [33]. Our study supports that a minimally invasive midline approach to posterior fusion using low-profile facet instrumentation has improved outcomes sustained over 5 years as compared to a traditional open midline fusion using relatively larger pedicle screws.

In conclusion, this study found shorter hospital stays and sustained superior outcomes for patients undergoing single-level circumferential lumbar spinal fusion with minimally invasive low-profile facet posterior instrumentation as compared to larger-profile pedicle screws, both of which procedures were performed via a midline approach. Postoperative MRI scans, however, found increased alteration in paraspinal muscle changes which was insignificantly greater for the pedicle relative to the facet screw group, but this may be attributable to an insufficient number of usable scans for this analysis.

**Acknowledgments** Funded by Midwest Spine Institute Research Division and Abbott Spine.

**Conflict of interest** None.

## References

1. Hsieh PC, Koski TR, O'Shaughnessy BA, Sugrue P, Salehi S, Ondra S, Liu JC (2007) Anterior lumbar interbody fusion in comparison with transforaminal lumbar interbody fusion: implications for the restoration of foraminal height, local disc angle, lumbar lordosis, and sagittal balance. *J Neurosurg Spine* 7(4): 379–386
2. Min JH, Jang JS, Jung BJ, Lee HY, Choi WC, Shim CS, Choi G, Lee SH (2008) The clinical characteristics and risk factors for the adjacent segment degeneration in instrumented lumbar fusion. *J Spinal Disord Tech* 21(5):305–309
3. Mura PP, Costaglioli M, Piredda M, Caboni S, Casula S (2011) TLIF for symptomatic disc degeneration: a retrospective study of 100 patients. *Eur Spine J* 20(Suppl 1):S57–S60
4. Freeman BJ, Licina P, Mehdian SH (2000) Posterior lumbar interbody fusion combined with instrumented postero-lateral fusion: 5-year results in 60 patients. *Eur Spine J* 9(1):42–46
5. Høy K, Bünger C, Niederman B, Helmig P, Hansen ES, Li H, Andersen T (2013) Transforaminal lumbar interbody fusion (TLIF) versus posterolateral instrumented fusion (PLF) in degenerative lumbar disorders: a randomized clinical trial with 2-year follow-up. *Eur Spine J* 22(9):2022–2029
6. Krishna M, Pollock RD, Bhatia C (2008) Incidence, etiology, classification, and management of neuralgia after posterior lumbar interbody fusion surgery in 226 patients. *Spine J* 8(2): 374–379
7. Rantanen J, Hurme M, Falck B, Alaranta H, Nykvist F, Lehto M, Einola S, Kalimo H (1993) The lumbar multifidus muscle five years after surgery for a lumbar intervertebral disc herniation. *Spine* 18(5):568–574
8. Taylor H, McGregor AH, Medhi-Zadeh S, Richards S, Kahn N, Zadeh JA, Hughes SP (2002) The impact of self-retaining retractors on the paraspinal muscles during posterior spinal surgery. *Spine* 27(24):2758–2762
9. Kim KT, Lee SH, Suk KS, Bae SC (2006) The quantitative analysis of tissue injury markers after mini-open lumbar fusion. *Spine* 31(6):712–716
10. Kikuchi Y, Nakamura T, Takayama S, Horiuchi Y, Toyama Y (2003) MR imaging in the diagnosis of denervated and reinnervated skeletal muscles: experimental study in rats. *Radiology* 229(3):861–867
11. Gejo R, Kawaguchi Y, Kondoh T, Tabuchi E, Matsui H, Torii K, Ono T, Kimura T (2000) Magnetic resonance imaging and histologic evidence of postoperative back muscle injury in rats. *Spine* 25:941–946
12. Remes V, Lamberg T, Tervahartiala P, Helenius I, Schlenzka D, Yrjönen T, Osterman K, Seitsalo S, Poussa M (2006) Long-term outcome after posterolateral, anterior, and circumferential fusion for high-grade isthmic spondylolisthesis in children and adolescents. Magnetic resonance imaging findings after average of 17-year follow-up. *Spine* 31(21):2491–2499
13. Gille O, Jolivet E, Dousset V, Degrise C, Obeid I, Vital JM, Skalli W (2007) Erector spinae muscle changes on magnetic resonance imaging following lumbar surgery through a posterior approach. *Spine* 32(11):1236–1241
14. Kamath S, Venkatanarasimha N, Walsh MA, Hughes PM (2008) MRI appearance of muscle denervation. *Skeletal Radiol* 37(5): 397–404

15. Gejo R, Matsui H, Kawaguchi Y, Ishihara H, Tsuji H (1999) Serial changes in trunk muscle performance after posterior lumbar surgery. *Spine* 24(10):1023–1028
16. Aeppli M, Mannion AF, Grob D (2009) Translaminar screw fixation of the lumbar spine: long-term outcome. *Spine* 34(14):1492–1498
17. Best NM, Sasso RC (2006) Efficacy of translaminar facet screw fixation in circumferential interbody fusions as compared to pedicle screw fixation. *J Spinal Disord Tech* 19(2):98–103
18. Beaubien BP, Mehbod AA, Kallemeier PM, Lew WD, Buttermann GR, Transfeldt EE, Wood KB (2004) Posterior augmentation of an anterior lumbar interbody fusion: minimally invasive fixation versus pedicle screws in vitro. *Spine* 29(19):E406–E412
19. Burton D, McIff T, Fox T, Lark R, Asher MA, Glattes RC (2005) Biomechanical analysis of posterior fixation techniques in a 360 degrees arthrodesis model. *Spine* 30:2765–2771
20. Razi AE, Spivak JM, Kummer FJ, Hersh DS, Goldstein JA (2011) Biomechanical comparison of translaminar screw versus pedicle screw supplementation of anterior femoral ring allografts in one-level lumbar spine fusion. *Bull NYU Hosp J Dis* 69(4):298–302
21. Kim DY, Lee SH, Chung SK, Lee HY (2004) Comparison of multifidus muscle atrophy and trunk extension muscle strength. *Spine* 30:123–129
22. Lee JC, Cha J-G, Kim Y, Kim Y-I, Shin B-J (2008) Quantitative analysis of back muscle degeneration in the patients with the degenerative lumbar flat back using a digital image analysis: comparison with the normal controls. *Spine* 33(3):318–325
23. Battié MC, Niemeläinen R, Gibbons LE, Dhillon S (2012) Is level- and side-specific multifidus asymmetry a marker for lumbar disc pathology? *Spine J* 12(10):932–939
24. Zigler J, Delamarter R, Spivak JM, Linovitz RJ, Danielson GO 3rd, Haider TT, Cammisa F, Zuchermann J, Balderston R, Kitchel S, Foley K, Watkins R, Bradford D, Yue J, Yuan H, Herkowitz H, Geiger D, Bendo J, Peppers T, Sachs B, Girardi F, Kropf M, Goldstein J (2007) Results of the prospective, randomized, multicenter Food and Drug Administration investigational device exemption study of the ProDisc-L total disc replacement versus circumferential fusion for the treatment of 1-level degenerative disc disease. *Spine* 32(11):1155–1162
25. Glassman S, Gornet MF, Branch C, Polly D Jr, Peloza J, Schwender JD, Carreon L (2006) MOS short form 36 and Oswestry Disability Index outcomes in lumbar fusion: a multicenter experience. *Spine J* 6(1):21–26
26. Jang JS, Lee SH (2005) Clinical analysis of percutaneous facet screw fixation after anterior lumbar interbody fusion. *J Neurosurg Spine* 3(1):40–46
27. Tuli S, Eichler ME, Woodard EJ (2005) Comparison of perioperative morbidity in translaminar facet versus pedicle screw fixation. *Orthopedics* 28(8):773–778
28. Tuli J, Tuli S, Eichler ME, Woodard EJ (2007) A comparison of long-term outcomes of translaminar facet screw fixation and pedicle screw fixation: a prospective study. *J Neurosurg Spine* 7(3):287–292
29. Carragee EJ, Don AS, Hurwitz EL, Cuellar JM, Carrino JA, Herzog R (2009) Does discography cause accelerated progression of degeneration changes in the lumbar disc: a ten-year matched cohort study. *Spine* 34(21):2338–2345
30. Fan SW, Hu ZJ, Fang XQ, Zhao FD, Huang Y, Yu HJ (2010) Comparison of paraspinal muscle injury in one-level lumbar posterior inter-body fusion: modified minimally invasive and traditional open approaches. *Orthop Surg* 2(3):194–200
31. Resnick DK, Choudhri TF, Dailey AT, Groff MW, Khoo L, Matz PG, Mummaneni P, Watters WC 3rd, Wang J, Walters BC, Hadley MN, American Association of Neurological Surgeons/Congress of Neurological Surgeons (2005) Guidelines for the performance of fusion procedures for degenerative disease of the lumbar spine. Part 11: interbody techniques for lumbar fusion. *J Neurosurg Spine* 2(6):692–699
32. Bendix T, Sorensen JS, Henriksson GA, Bolstad JE, Narvestad EK, Jensen TS (2012) Lumbar modic changes—a comparison between findings at low- and high-field magnetic resonance imaging. *Spine* 37(20):1756–1762
33. Habib A, Smith ZA, Lawton CD, Fessler RG (2012) Minimally invasive transforaminal lumbar interbody fusion: a perspective on current evidence and clinical knowledge. *Minim Invasive Surg* 1:1–9